

# 牙體復形學會病例報告競賽摘要稿紙

摘要截收日期：114年8月11日

1. 報名者基本資料:

姓名：方曄

通訊處：

電話：

傳真：\_\_\_\_\_

電子信箱：\_\_\_\_\_

報名 Junior 組(實習牙醫學生、PGY) 報名 Senior 組(受訓住院醫師或以上) 會員 非會員(待入會)

PS. 非會員，需於會前辦理入會手續

2. 病例分類(請勾選一個治療項目作病例報告)：

齒色材料直接充填

嵌體治療(齒色)

嵌體治療(金屬)

瓷牙貼面(包括全瓷冠)

深度齲齒

綜合複雜病例治療

3. 收件處：

100 台北市常德街 1 號景福館 203A 室(中華民國牙體復形學會)

電話：(02)2382-6145 傳真：(02)2370-0386

聯絡人：吳小姐

電子信箱：[oda@od.url.tw](mailto:oda@od.url.tw)

請以電子郵件投稿至學會電子信箱

4. 審查結果(學會專用)

接受 審委簽名：

修正 理由：

婉拒 理由：

# 牙體復形學會病例報告競賽摘要

(請完成下列內容，可依需要增設項目)

Junior 組  Senior 組

病例符合分類：

齒色材料直接充填

瓷牙貼面 (包括全瓷冠)

嵌體治療 (齒色)

深度齲齒

嵌體治療 (金屬)

綜合複雜病例治療

## 患者基本資料

姓名 (name) : 鄒O庭

年齡 (age) : 40

主訴 (chief complain) : Soreness over upper right teeth, and hoped for full mouth evaluation of old restorations

病史 (past medical and dental history) :

This 40 y/o female patient was a case of multiple caries. She found soreness over upper right area for 2 weeks and thus came to our department for evaluation. Besides, she also asked for full-mouth evaluation for old restorations.

**Past medical history**

denied any systemic diseases

NFADA

Alcohol: (-)Betel nut: (-)Cigarette: (-)

Bruxism: (-)

問題所在 (problem list) :

Tooth 14.16.26.46 dental caries

Tooth15.24.25.34.35.36

-old amalgam and resin filling with overhang and poor profile

Chronic gingivitis

Tooth 17.27 old resin filling with discoloration

Tooth 17.27 buccal crossbite

診斷 (diagnosis) :

Tooth 14.16.26.46

Chronic gingivitis

**治療計畫：**

Tooth 14.15.16.17.24.25.26.27.34.35.36.46

Tooth 15.24.25.34.35.46 :

Operative dentistry TX

Tooth 17.27

Option 1: OHI, keep f/u

Option 2: Operative dentistry TX

Tooth 14.16.26.36

缺損範圍較大

Option 1: inlay/onlay

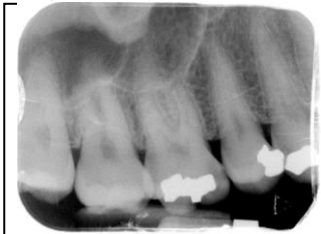Option 2: Operative dentistry TX

Patient chose option 1

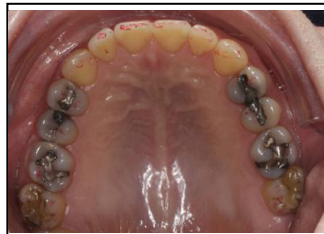**治療過程及照片** (包括口內照、X光片；與美學相關者須附口外照)

**治療過程：**

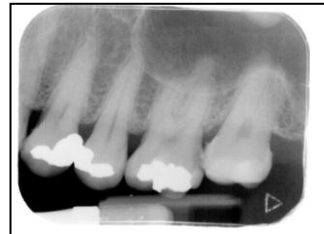**治療前照片：**



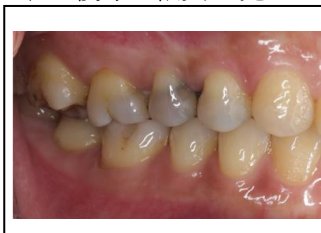右上後牙區根尖 X 光



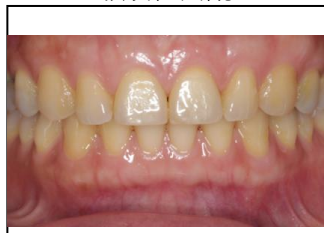上顎咬合面觀



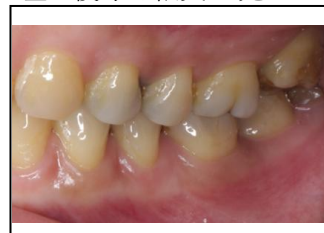左上後牙區根尖 X 光



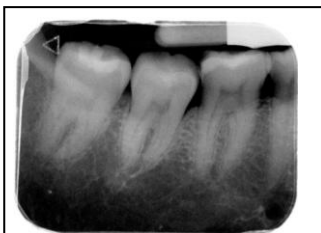右側正中咬合觀



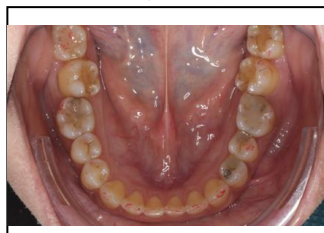
正面正中咬合觀



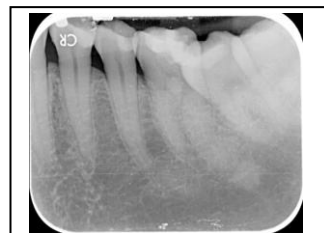左側正中咬合觀



右下後牙區根尖 X 光

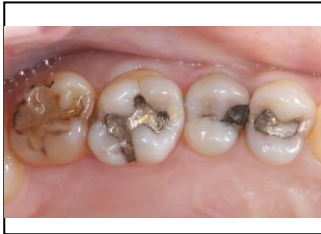

下顎咬合面觀

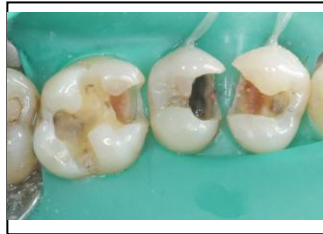

左下後牙區根尖 X 光

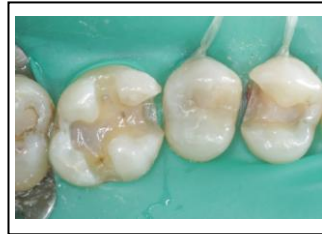
治療中照片：



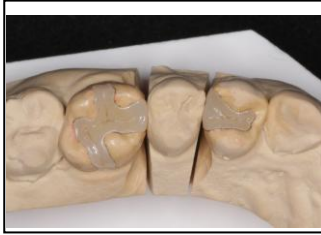Tooth 14-17 咬合面觀



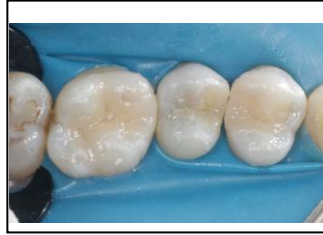Tooth 14-16 caries removal



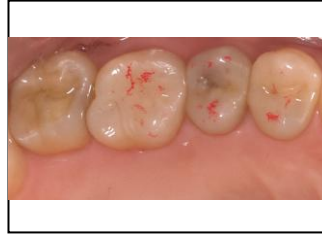Tooth 14,16 CDO, Tooth 15 OD



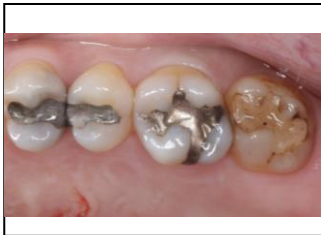Tooth 14.16 inlay



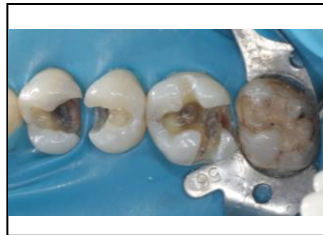Tooth 14.16 inlay delivery



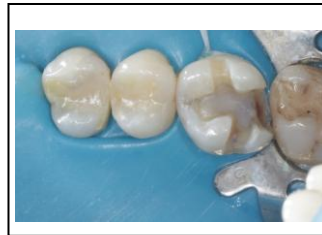Tooth 17 OD



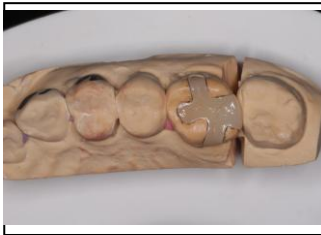
Tooth 24-27 咬合面觀



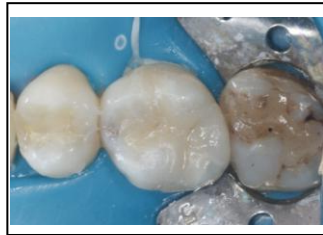Tooth 24-26 caries removal



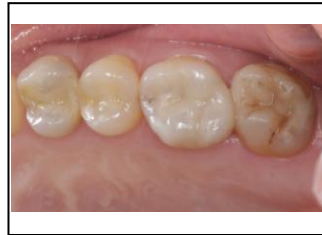Tooth 24,25 OD, Tooth 26 CDO



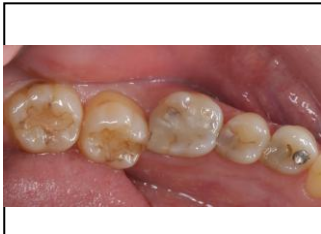Tooth 26 inlay



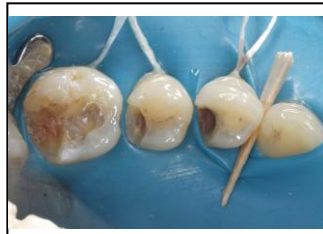Tooth 26 inlay delivery



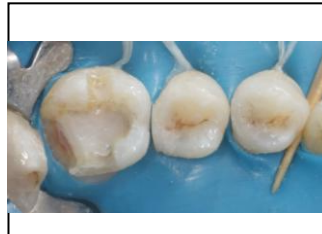Tooth 27 OD



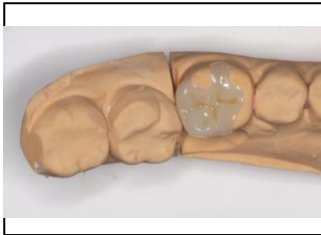
Tooth 34-38 咬合面觀



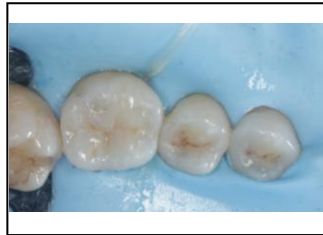Tooth 34-36 caries removal



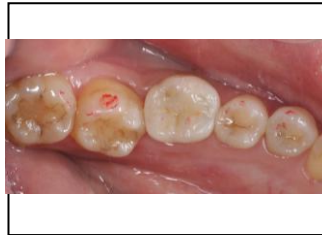Tooth 34,35 OD, Tooth 36 CDO



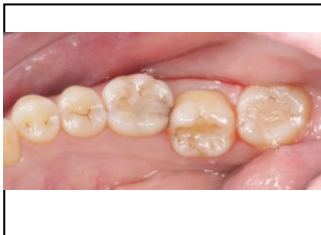Tooth 36 onlay



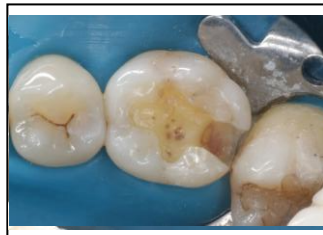
Tooth 36 onlay delivery



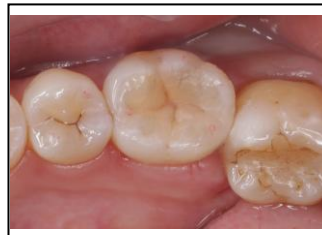Finishing and polishing



Tooth 44-48 咬合面觀

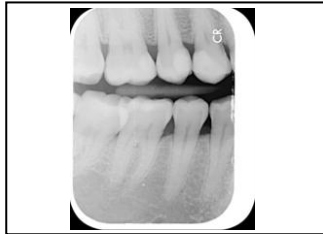

Tooth 46 caries removal

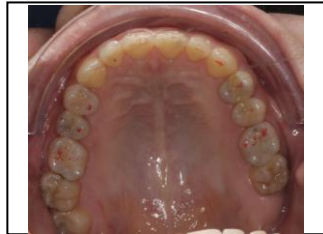

Tooth 46 OD

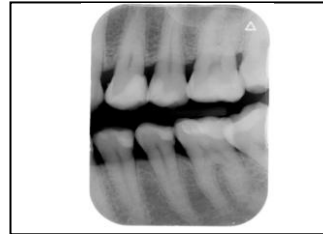## 治療後照片：



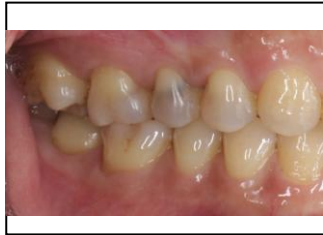右後小白齒區咬翼 X 光



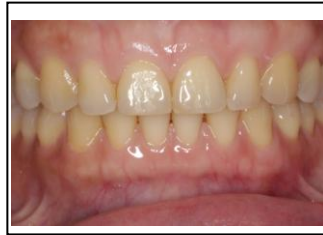上顎咬合面觀



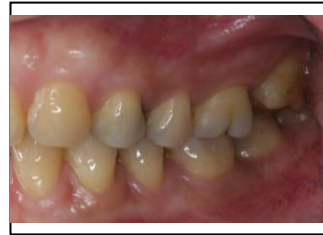左後小白齒區咬翼 X 光



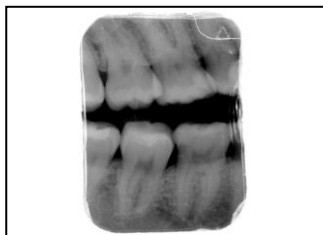右側正中咬合觀



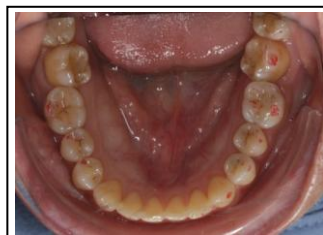正面正中咬合觀



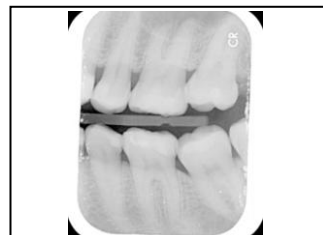左側正中咬合觀



右後白齒區咬翼 X 光



下顎咬合面觀



左後白齒區咬翼 X 光

## 討論與結論：

### Discussion:

This case involved the management of multiple caries and replacement of old restorations with overhang, ill-fitting margin, or discoloration in posterior teeth. A comprehensive restorative approach was adopted, including direct composite resin filling for small to moderate defects, and ceramic inlays for teeth with extensive structural loss. The decision was based on preserving sound tooth structure while restoring function and esthetics. Composite resin was applied using an incremental layering technique to minimize polymerization shrinkage. For ceramic inlays, adhesive bonding protocols were strictly followed to optimize retention and marginal integrity. So far, the follow-up demonstrated favorable short-term clinical outcomes, with good functional performance and no signs of recurrent caries or marginal leakage.

### Conclusion:

The combination of composite resin and ceramic restorations offers a reliable and conservative solution for managing multiple carious lesions and replacing old restorations. Careful case selection, adhesive protocols, and proper restorative techniques are key to clinical success. Regular follow-up is essential to ensure long-term stability and early detection of any potential complications.